# Adapting CBCT in private practice: A personal experience

**Author**_Dr Barry Kaplan, USA

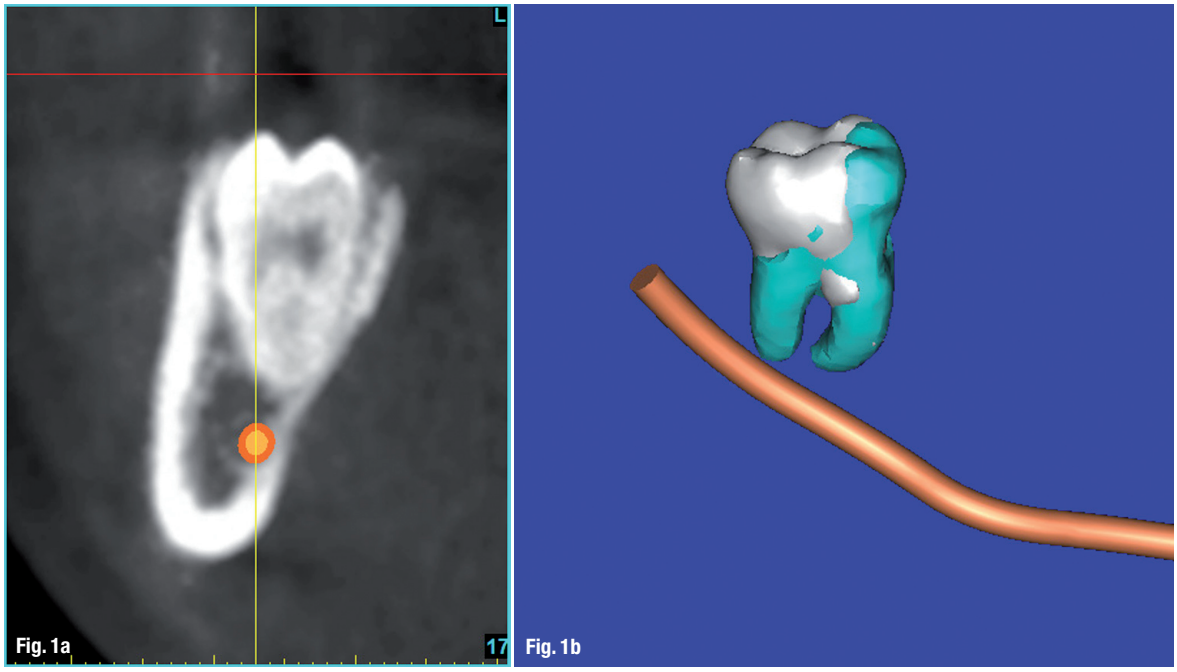


**Fig. 1a**_A cross-sectional view of the mandibular right third molar showing its proximity to the mandibular nerve. **Fig. 1b**_Same view using third-party 3-D software (SimPlant, Materialise Dental). The software uses the DICOM data obtained from the scan.

_**Consider the allegory** of a pilot navigating a plane with no cockpit controls and poor visibility. It is too dark to see, and there are no reference points to help the pilot guide the plane. At this point, the sky is a 2-D world. This scenario is frightening to even the most skilled pilots: navigating the unknown.

Implant dentistry offers similar challenges in navigating the implant properly into the receptor site so that it meets the surgical and prosthetic goals of the plan. In order to achieve proper implant placement, we need predictability.

As a trained prosthodontist, it has always been my goal to achieve a high degree of predictability. When evaluating implant receptor sites, I realised early on the need for top-down cognition during the treatment planning process.

In other words, the teeth are first visualised in their ideal prosthetic position and then the implants are planned in each potential receptor site to best suit the intended position of the teeth or occlusion. Unless you control those steps, the process is guided by a level of guesswork, and therefore you are not flying with full control.

It is well established that a 2-D radiograph and/or panoramic radiograph of the bone does not provide the information necessary to fully appreciate the spatial topography of the 3-D receptor site. An analogy would be observing two stars that appear close together in the night sky that are actually light-years apart.

Another issue with 2-D radiographic modalities is that they have varying degrees of distortion. Once I realised that there were these types of errors with 2-D imaging, I came to the understanding that 3-D imaging gave me the best chance of optimising control of implant placement, and avoiding vital adjacent anatomy.

Prior to the last decade, the only way to access this technology was by referring your patient to the hospital radiology department or imaging centre for a medical-grade CT. In that venue, we lacked control of some of the process, including proper head position, optimum slice thickness, resolution and higher radiation exposure which may have affected the diagnostic quality of the images. All of this changed with the advent of CBCT scanning devices that have made the 3-D technology accessible to the dental profession in a cost-effective way.

My early attempt to interface with 3-D imaging technology was to send the patient to a separate location for a CBCT scan. This posed some logistical problems in terms of having the patient scheduled in a timely fashion, and was inconvenient, as this required going to a unfamiliar facility. Many patients will lose motivation when too many barriers are encountered, such as travelling to a distant centre for image acquisition.

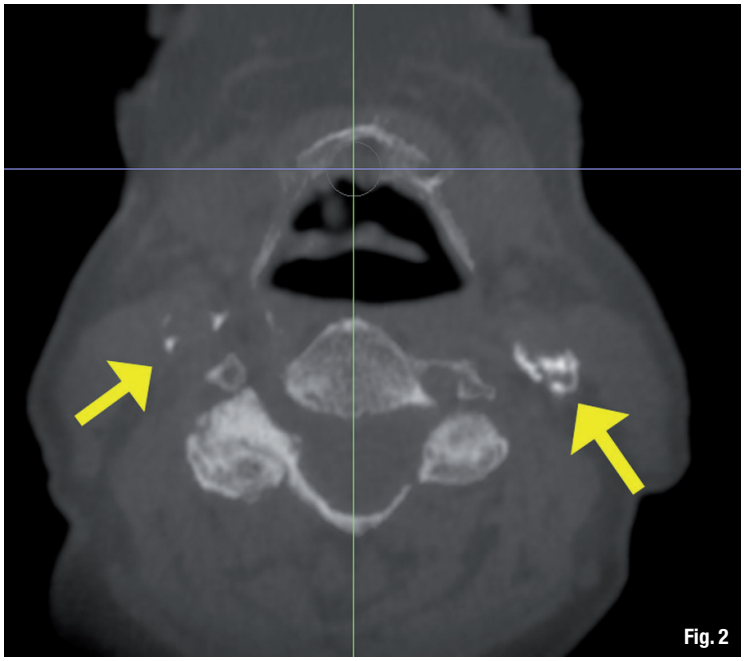


**Fig. 2**_An axial slice revealing carotid artery calcification (yellow arrows).

It was still essential that the patient's head was properly positioned in the machine. If the head is not positioned properly, erroneous information may be gleaned from the cross-sectional images.

Another potential source of error in a large imaging centre is whether the machines are periodically calibrated to insure consistent accuracy. Lastly, unless the doctor is present during the image acquisition (at the imaging centre), he or she is unable to ensure that pre-scan details are attended to (e.g. cotton rolls between the teeth or the proper seating of a radiopaque scanning appliance).

In order to overcome some of these issues, my next progression was to try a mobile imaging service. A specially equipped van fitted with a

**Fig. 3a**_A digital panoramic radiograph (from CBCT) showing large ameloblastoma in the mandible.
**Fig. 3b**_A cross-sectional slice of the mandibular left molar area showing destruction by the ameloblastoma of the buccal plate.

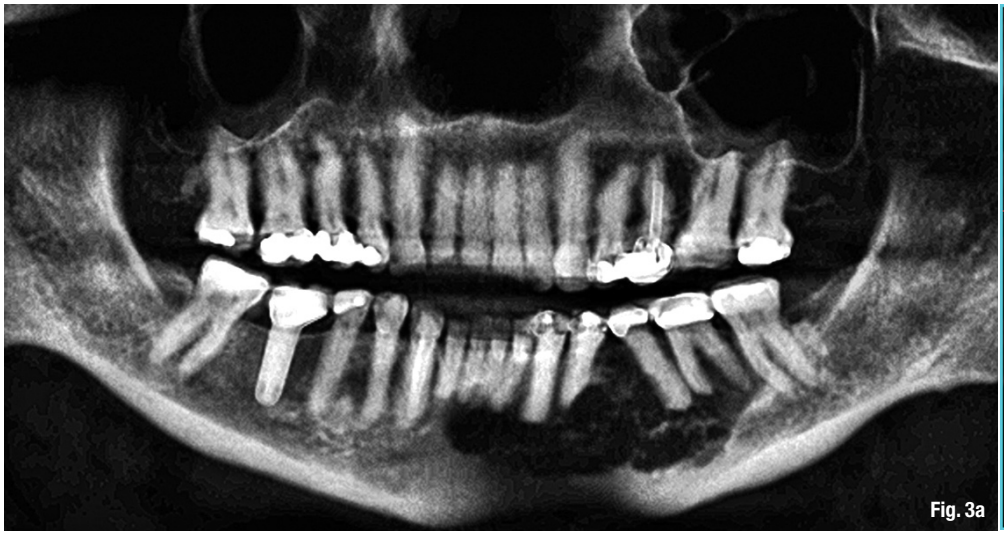


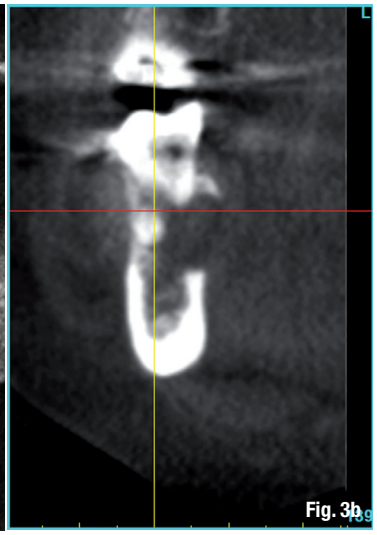

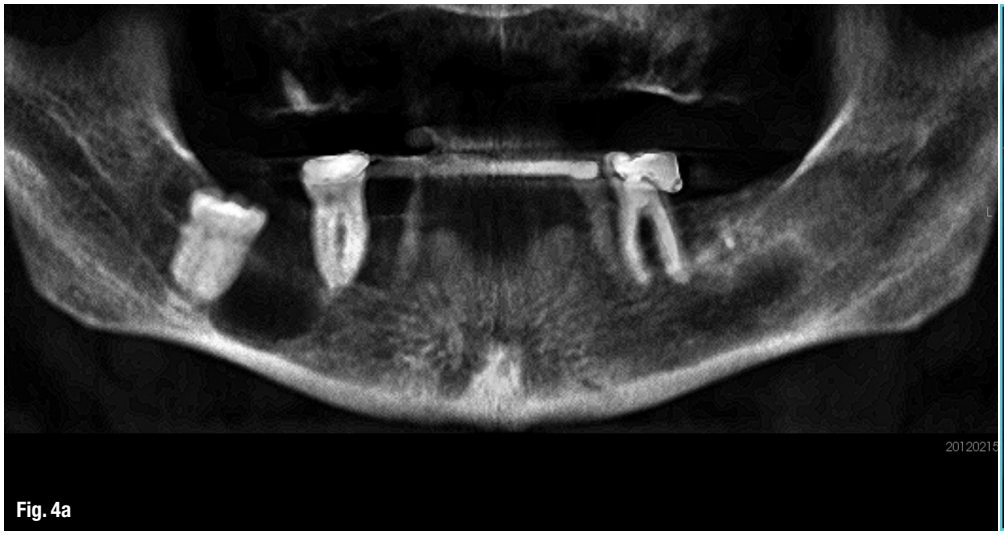


Fig. 4a

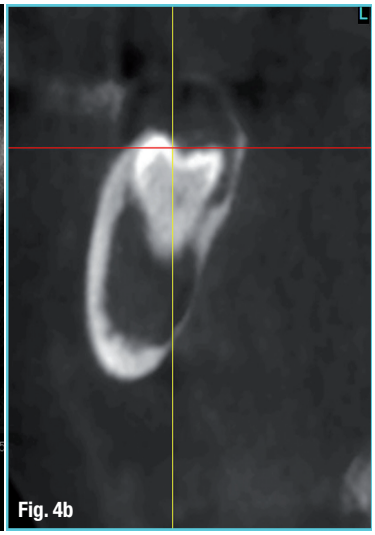

Fig. 4b

**Fig. 4a**_A digital panoramic radiograph (from CBCT) showing a large odontogenic cyst in the mandibular right side.
**Fig. 4b**_A cross-sectional slice of the mandibular right molar area showing large-area destruction by the cyst.

CBCT device will travel to your office or the patient's home. Although this is much more convenient for the patient, reliability of these services is sometimes questionable and there may be concerns again about calibration due to relatively imperfect road surfaces, which may cause the machine to bounce around in the van. In addition, there may be issues with transferring the data, depending on the software applications that are to be used.

All of the points in contention were resolved when I decided to purchase a CBCT device for my office. After investigating all of the machines, I decided on an i-CAT Classic (Imaging Sciences)

Having CBCT technology in the office has provided me with the control that I desired and has made a dramatic change in our daily workflow, with instant access to the technology. Literally within seconds, patient anatomy can be viewed in three different orthogonal views (axial, coronal and sagittal), as well as a 3-D reconstructed solid model view—all with total interactivity afforded to me through the software applications.

The complete visualisation of the anatomy can be viewed and information assessed almost immediately. Treatment planning is expedited, since the patient does not have to schedule an appointment at a separate location. In addition to passively viewing the images on the LCD screen, the data can be imported into third-party software that allows for virtual 3-D implant placement, providing me with the tools that I need to remove all of the guesswork associated with 2-D imaging.

The treatment plan can be shown on a large screen in my office or on my laptop to each patient, greatly enhancing treatment acceptance. Once accepted by the patient, the treatment plan can then be accurately carried out via a surgical guided derived from the 3-D planning software.

Other advantages of CBCT imaging in the office that I have found highly rewarding are airway analysis for sleep apnoea patients; interpretation of hard-tissue pathology (Figs. 3a & b, 4a & b); identification of vital structures during oral surgery procedures (Figs. 1a & b), such as third-molar extractions; periodontic/endodontic evaluations; and identification of radiopacities suggestive of carotid artery calcification, requiring further evaluation by a radiologist (Fig. 2).

Having CBCT in the office has allowed me to have a greater understanding and appreciation of the anatomy and related structures of each patient. This knowledge is then applied during the treatment planning process to determine which tissues are deficient and with careful attention to vital structures so that implants can be placed in the most optimal receptor sites. Honestly, I do not know how I could practice without a CBCT device in my office today._

## _about the author

cone beam

**Dr Barry Kaplan**, Prosthodontist, Bloomfield, N.J., USA. Past President of the NJ Section of the American College of Prosthodontists, Fellow of the International Congress of Oral Implantologists (ICOI).

www.kaplandentistrynj.com